

Fractional, Non-Ablative Laser Therapy for the Treatment of Striae Distensae

Francesca de Angelis, MD – Specialists in Plastic Surgery, Naples, Italy

Maurice A. Adatto, MD - Skinpulse Dermatology & Laser Center, Geneva, Switzerland

Overview

Fractional, non-ablative laser therapy has the potential to effectively treat striae on multiple fronts: photothermolysis of microvasculature resolves violaceous erythema, and replacement of scar tissue with healthy, normal tissue normalizes hyper- and hypo-pigmentation. Clinical observations described in this report using the 1540 nm erbium glass laser (the Lux1540™ handpiece, Palomar Medical Technologies, Inc., Burlington, MA) include significant improvements in the pigmentation and appearance of striae* using a wavelength that is safe and effective for all skin types.

Introduction

Striae distensae, or stretch marks, are linear scars in the dermis which arise from rapid stretching of the skin over weakened connective tissue (1). Histology of mature striae reveals thin and retracted collagen and elastin fibers resulting in a lack of supporting material and an atrophied epidermis (2). While striae occur equally among races, they are more prevalent in women (3). Striae may result from a number of causes, including, but not limited to, rapid changes in weight, adolescent growth spurts, corticosteroid use or Cushing Syndrome, and generally appear on the buttocks, thighs, knees, calves, or lumbosacral areas (3-5). In addition, approximately 90% of all pregnant women develop stretch marks either on their breasts and/or abdomen by the third trimester (6). The three maturation stages of striae include the acute stage (striae rubrae) characterized by raised, erythematous striae, the sub-acute stage characterized by purpuric striae, and the chronic stage (striae albae), characterized by white or hypo-pigmented, atrophied striae (7).

Currently, there is no surgical therapy which significantly improves the appearance of striae and is safe for all skin types (8). Studies using topical tretinoin resulted in some improvements, but efficacy was limited to only early, active striae (9,10). A combination treatment using sand abrasion and 15% trichloroacetic acid has demonstrated

efficacy in the treatment of all types of striae; however, there is a learning curve for physicians using this open wound technique, and a positive outcome is dependent upon the patient's strict adherence to post-wound care instructions (11). Additional drawbacks include the significant downtime, up to a week for large areas, and the increased risk of post-inflammatory hyper-pigmentation (PIH) for patients with darker skin types, e.g., skin types V and VI (11).

Treatments with either UVB light therapy or XeCL 308 nm excimer laser yielded only transient results with study authors recommending that subjects receive additional treatments every one to four months to maintain benefits (2,12). Between two small clinical studies examining the use of intense-pulsed light for striae, one reported positive histological changes that were unmatched by clinical and patient evaluations and the other reported PIH (8,13). PIH was also observed in multiple studies using the 585 nm pulsed-dye laser (PDL) (1,14-16). In a comparison study with the 585 nm PDL and the short-pulsed CO2 laser, persistent erythema was observed in a subject with type IV skin and marked PIH in a subject with type VI skin (17). The difficulty of treating striae distensae in darker-skinned patients was further underscored by negative results from another study examining the use of the 1450 diode laser (18). Given the limitations and associated risks of laser systems using cryogen-based cooling, there is a need for alternative treatment therapies for striae. Fractional laser therapy represents a newer treatment option whose efficacy has only been tested in one published study thus far. In a small study by Kim et al, subjects with skin types ranging from III-IV were treated with the 1550 nm erbium-doped fractional laser (7). Results showed increased production of collagen and elastin but only transient restoration of pigmentation (7).

The results presented in this brief report describe the use of another fractional erbium laser (Lux1540™) in a small number of subjects with skin types ranging from III-VI. Advantages of using fractional photothermolysis include the superior depth of coagulated tissue, minimal side

* Pending U.S. FDA Clearance for striae. The Lux1540™ has received FDA Clearance for skin resurfacing, coagulation, and for the treatment of surgical scars, acne scars, and melasma.

effects, minimal pain, and little to no downtime. By generating micro-columns of coagulated tissue through the epidermis into the dermis, fractional technology evokes a wound healing response which results in the significant and permanent improvement of deep scars such as striae. Healthy tissue surrounding the micro-columns enables pigment normalization and rapid re-epithelialization within the micro-column. The 1540 nm wavelength is selective for water in the tissue, not melanin, making the treatment safe for all skin types. As a result, subjects with darker skin types (IV-VI) are not at increased risk for prolonged PIH as they are following treatment with the 585 nm PDL, intense pulsed light, or short-pulsed CO₂ (1,8,14,16,17). Our clinical data strongly supports the use of the Lux1540™ for the treatment of striae distensae in all skin types.

Treatment Protocol for Striae

With the Lux1540™ device, practitioners can tailor their treatment parameters depending on the maturation stage, depth, and pigmentation of the striae. Using interchangeable optics, practitioners can select the 10 mm tip (100 mb/cm² density) to deliver higher energy settings for deeper striae and the 15 mm tip (320 mb/cm² density) to deliver lower energy, higher density settings for more superficial striae with pigmentation. In this clinical study, striae were treated with a range of energy from 34-50 mJ/mb and three to six passes per treatment for a total coverage of 600 mb/cm² to 1200 mb/cm². The dramatic clinical improvements observed may be due to the treatment of an expanse of tissue that was wider than the striae, thus allowing for more extensive removal and replacement of scar tissue with healthy, normal tissue.

Histology Profile

To establish appropriate treatment settings for our clinical studies and to understand the full range of coagulative depth possible with the Lux1540™ device, we performed histological analyses using ex vivo Yucatan pig abdominal skin. Visualization of the thermally coagulated columns was achieved with Hematoxylin and Eosin (H&E) stain and cross-polarized light. Using energy settings of 52 mJ/mb, close to the clinical treatment range, we created micro-columns of coagulated tissue approximately 700 μm deep (not shown). Increasing the energy to 100 mJ/mb yielded even deeper coagulation columns of approximately 1 mm in depth. (Fig. 1A-B).

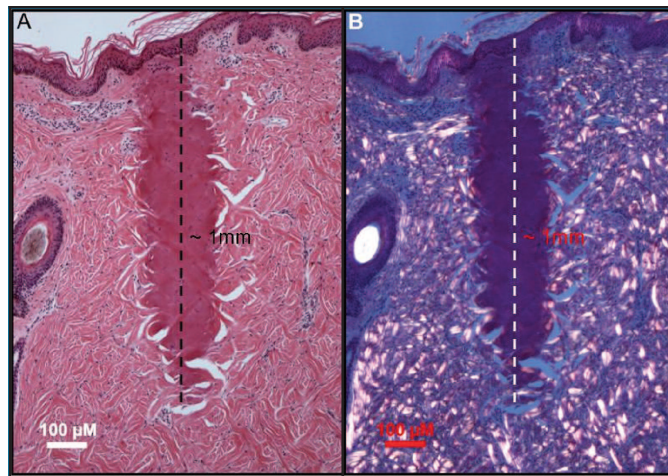


Figure 1. Ex vivo Yucatan Pig Histology Showing Depth of Coagulation. A) H&E stain reveals a coagulation column of 1 mm depth with 100 mJ/mb treatment. B) Cross-polarized light allows for even greater visualization of the micro-columns of coagulated tissue.

Results: Clinical Observations

Efficacy data collected from our clinical subjects demonstrate the ability of the Lux1540™ to treat a range of striae in varying degrees of maturation, from rubrae to albae. Subjects tolerated the treatments well with only a minority of subjects requiring application of a Cool Roller™, ice, or topical anesthetics during treatment. Immediate side effects were limited to transient edema and erythema for lighter-skinned subjects with the addition of transient PIH for a few darker-skinned subjects which was resolved by either the first or second month follow-up visit. There were no long-term side effects. Investigator-assessed improvement scores revealed that all treated striae exhibited improvements of 50% or more and many exhibited even higher improvement scores. The significance of these results is further highlighted by the fact that a large majority of the subjects had Fitzpatrick skin types III-VI which historically develop prolonged PIH following laser treatment (1,14,15). Some examples of the significant improvements observed in older striae (7 – 20 years old) treated with the Lux1540™ are shown in Figures 2-5.

Figure 2 shows a female subject with 19 year-old bilateral vertical striae on her lower abdomen prior to treatment (Fig. 2A, see right panel for enlargement of striae). Treatments with the Lux1540™ were performed on one side, allowing for direct comparison to untreated striae on the other side for efficacy evaluations. After four

treatments with three passes (total coverage of 600 mb/cm²), the striae blended almost seamlessly with nearby normal skin due to resolution of the hyper-pigmentation and improvements in the overall appearance of the scar (compare areas within dotted circle in Fig. 2A and 2B).

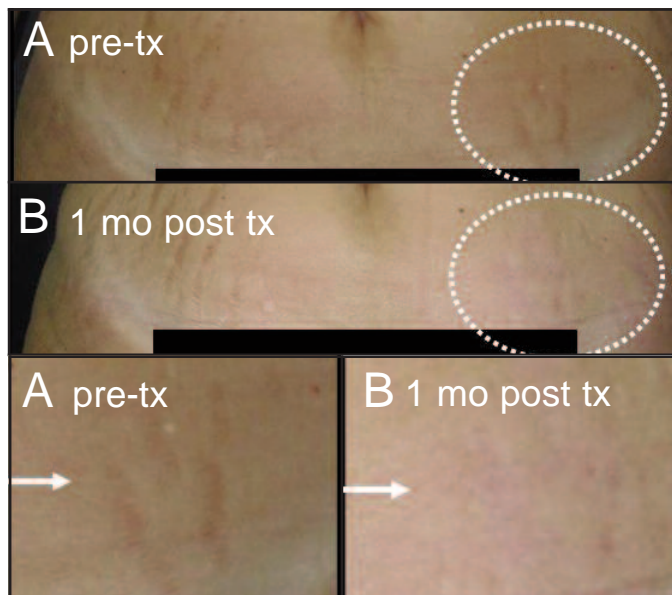


Figure 2. Proficiency of Lux1540™ in Treating Abdominal Striae. A) Pre-treatment, subject's striae appear hyper-pigmented and depressed. C) Post-treatment, the treated area (within dotted circle) appears softer and the hyper-pigmentation has resolved. Arrows point to enlargements of treated areas.

The subject in Figure 3 has 20 year-old bilateral horizontal striae alba on her lower back before treatment (Fig. 3A). In order to compare the efficacy of the two different optics, this subject received treatment with the Lux1540™ 10 mm tip on her left side and the 15 mm tip on her right side. One month after one treatment with six passes (total coverage of 1200 mb/cm²), the striae on both sides are indiscernible (Fig. 3B, area within dotted box). Despite the advanced maturation stage of the subject's striae, characterized by linear, hypo-pigmented depressions, Lux1540™ treatment appears to result in re-pigmentation and there is a much smoother transition from scar tissue to the normal surrounding skin.

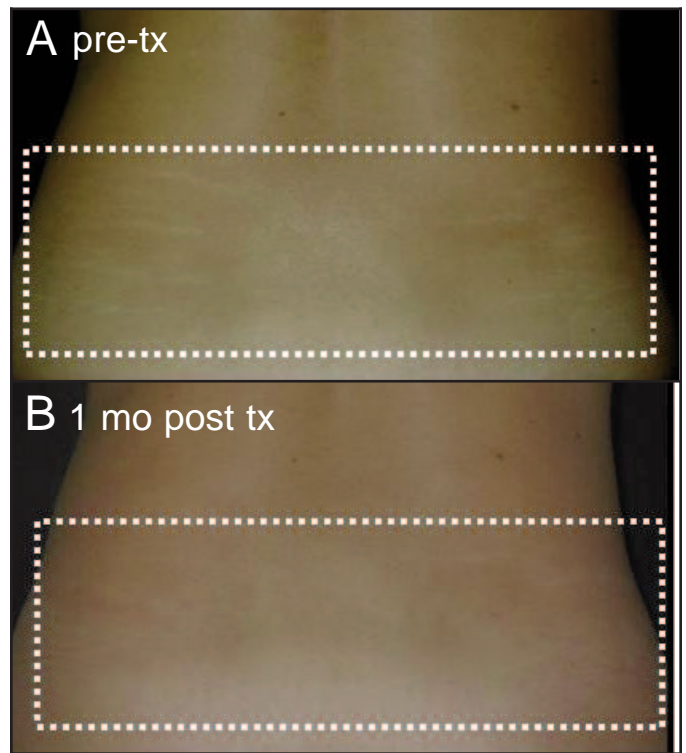


Figure 3. Re-pigmentation of Horizontal Striae Albae on Lower Back after Lux1540™ Treatment. A) Subject has hypo-pigmented striae on left and right side of lower back prior to treatment. B) Normalization of pigment occurs equally on both sides, regardless of the handpiece tip used. Note: Left side was treated with the 10 mm tip and right side with the 15 mm tip.

Figure 4 shows an example of a female with 7 year-old horizontal striae albae on her breast, a common side effect of pregnancy. Prior to treatment with the Lux1540™, the hypo-pigmented striae spanned the height of the breast (Fig. 4A, area within dotted half-circle). After four treatments with three passes (total coverage of 600 mb/cm²), the appearance of the subject's striae are markedly improved with near-complete re-pigmentation and a return of natural skin appearance (Fig. 4B).




Figure 4. Global Improvement of Striae in the Breast. A) Subject has numerous striae in the breast (encapsulated within blue dotted line) before Lux1540™ treatment. B) One month after treatment, striae are visibly reduced.

Given the challenges of delivering effective results to darker-skinned subjects without the accompanying side effect of PIH, the results shown in Figure 5 for a skin type VI subject are quite dramatic. Prior to treatment, the subject had numerous striae albae across her upper thigh (Fig. 5A). Two Lux1540™ treatments were performed one month apart with two rotating passes at 40 mJ/mb in the central region of the subject's thigh, allowing for direct comparison to the flanking regions of untreated striae. In addition, the subject also received one treatment with the LuxDeepIR™ fractional infrared handpiece (Palomar Medical Technologies, Inc., Burlington, MA) at 110 J/cm². Immediately following treatment, localized spots of edema developed and were quickly resolved (Fig. 5B). One month after two treatments, the striae are barely visible due to normalization of both pigment and skin tone.




Figure 5. No PIH Observed Following Treatment with the Lux1540™ and LuxDeepIR™ in Subject with Fitzpatrick Skin Type VI. A) Before treatment, subject has highly pronounced striae on her upper thigh. B) Immediately post-treatment, the area within the dotted box displays localized swelling. C) Compared to the untreated striae outside the box, treated striae appear almost completely resolved by one month post-treatment. Note the normalization of pigment.

Discussion

The two major drawbacks of current treatments for striae distensae are transient improvements requiring inconvenient maintenance treatments and an increased risk of post-treatment PIH among darker-skinned patients. Our preliminary testing with the Lux1540™ device suggests these two drawbacks can be adequately addressed as demonstrated by the fact that there was no recurrence of striae in patients followed for 15 months and by the fact that this population included patients with darker skin types (IV-VI). One of the unique features of the device which significantly reduces the risk of PIH is its user-selectable tips enabling practitioners to tweak treatment settings depending on the subject's skin type. Reduced risk for PIH with the Lux1540™ can also be attributed to the selectivity of the wavelength for water, not melanin. Fractional delivery of columns of coagulation results in minimal side effects like edema and erythema, little to no downtime, and minimal pain for subjects. Ex vivo Yucatan pig histology illustrates the capability of the Lux1540™ to create fractional micro-columns of coagulated tissue as deep as 1 mm following treatment at 100 mJ/mb. With energy settings of 52 mJ/mb, close to the clinical treatment range, the fractional micro-columns are approximately 700 µm in depth. Our efficacy data demonstrate the ability of the Lux1540™ to normalize hyper-pigmented striae and to re-pigment striae albae due to the removal and replacement of the coagulated columns of tissue with new healthy tissue. The clinical photos shown here confirm the effectiveness of the Lux1540™ in treating striae on various anatomical locations, including the abdomen, lumbosacral region, breast and thigh. In addition to the reduced side effects and downtime, Lux1540™ treatments appear to be the only laser treatment associated with significant changes in the appearance and pigmentation of striae.

Conclusion

Fractional photothermolysis with the Lux1540™ dramatically improves a wide range of striae, regardless of the depth, pigmentation abnormalities, anatomical location and duration of the striae. In contrast to the prolonged erythema and PIH observed in darker-skinned subjects with the 585 nm PDL and the short-pulsed CO₂ lasers, the Lux1540™ appears to be safe and effective for all skin types.

References

1. McDaniel DH. Laser therapy of stretch marks. *Dermatol Clin* 2002; 20(1):67-76, viii.
2. Goldberg DJ, Marmur ES, Schmults C, Hussain M, Phelps R. Histologic and ultrastructural analysis of ultraviolet B laser and light source treatment of leukoderma in striae distensae. *Dermatol Surg* 2005; 31(4):385-387.
3. Cho S, Park ES, Lee DH, Li K, Chung JH. Clinical features and risk factors for striae distensae in Korean adolescents. *J Eur Acad Dermatol Venereol* 2006; 20(9):1108-1113.
4. Nieman LK, Ilias I. Evaluation and treatment of Cushing's syndrome. *Am J Med* 2005; 118(12):1340-1346.
5. Zheng P, Lavker RM, Kligman AM. Anatomy of striae. *Br J Dermatol* 1985; 112(2):185-193.
6. Tunzi M, Gray GR. Common skin conditions during pregnancy. *Am Fam Physician* 2007; 75(2):211-218.
7. Kim BJ, Lee DH, Kim MN, Song KY, Cho WI, Lee CK, Kim JY, Kwon OS. Fractional photothermolysis for the treatment of striae distensae in asian skin. *Am J Clin Dermatol* 2008; 9(1):33-37.
8. Hernandez-Perez E, Colombo-Charrier E, Valencia-Ibiett E. Intense pulsed light in the treatment of striae distensae. *Dermatol Surg* 2002; 28(12):1124-1130.
9. Rangel O, Arias I, Garcia E, Lopez-Padilla S. Topical tretinoin 0.1% for pregnancy-related abdominal striae: an open-label, multicenter, prospective study. *Adv Ther* 2001; 18(4):181-186.
10. Kang S, Kim KJ, Griffiths CE, Wong TY, Talwar HS, Fisher GJ, Gordon D, Hamilton TA, Ellis CN, Voorhees JJ. Topical tretinoin (retinoic acid) improves early stretch marks. *Arch Dermatol* 1996; 132(5):519-526.
11. Adatto MA, Deprez P. Striae treated by a novel combination treatment--sand abrasion and a patent mixture containing 15% trichloroacetic acid followed by 6-24 hrs of a patent cream under plastic occlusion. *J Cosmet Dermatol* 2003; 2(2):61-67.
12. Alexiades-Armenakas MR, Bernstein LJ, Friedman PM, Geronemus RG. The safety and efficacy of the 308-nm excimer laser for pigment correction of hypopigmented scars and striae alba. *Arch Dermatol* 2004; 140(8):955-960.
13. Trelles MA, Levy JL, Ghersetich I. Effects Achieved on Stretch Marks by a Nonfractional Broadband Infrared Light System Treatment. *Aesthetic Plast Surg* 2008.
14. Jimenez GP, Flores F, Berman B, Gunja-Smith Z. Treatment of striae rubra and striae alba with the 585-nm pulsed-dye laser. *Dermatol Surg* 2003; 29(4):362-365.
15. McDaniel DH, Ash K, Zukowski M. Treatment of stretch marks with the 585-nm flashlamp-pumped pulsed dye laser. *Dermatol Surg* 1996; 22(4):332-337.
16. Suh DH, Chang KY, Son HC, Ryu JH, Lee SJ, Song KY. Radiofrequency and 585-nm pulsed dye laser treatment of striae distensae: a report of 37 Asian patients. *Dermatol Surg* 2007; 33(1):29-34.
17. Nouri K, Romagosa R, Chartier T, Bowes L, Spencer JM. Comparison of the 585 nm pulse dye laser and the short pulsed CO2 laser in the treatment of striae distensae in skin types IV and VI. *Dermatol Surg* 1999; 25(5):368-370.
18. Tay YK, Kwok C, Tan E. Non-ablative 1,450-nm diode laser treatment of striae distensae. *Lasers Surg Med* 2006; 38(3):196-199.