

Tattoo and Nevus of Ota Removal With Q-Switched Ruby Laser: Case Reports

Eric Bernstein, MD; Robert Adrian, MD

This article presents 3 case reports of decorative tattoo removal and 1 case report of nevus of Ota removal with the Sinon 694-nm Q-switched ruby laser. No treatment-related adverse events were reported, and excellent clearance was achieved in all 4 patients.

As the popularity, visibility, and social acceptability of tattooing increases in the United States and elsewhere, so does the demand for fast, safe, and effective tattoo removal. The goal of tattoo removal is to completely clear, or at least dramatically lighten, tattoos without adversely altering the skin's appearance and texture. Treatments such as salabrasion, dermabrasion, and cryosurgery can lighten and sometimes fully clear tattoos, but these and other destructive modalities can cause permanent scarring.¹ Laser tattoo removal is the treatment of choice for removal of amateur and professional tattoos of all colors and in all skin types.¹⁻⁴ Because of the small size of tattoo particles, pulses in the nanosecond domain are required for tattoo removal.⁵ Q-switched lasers deliver pulses in the nanosecond domain and are the optimal devices for tattoo removal. In the past, Q-switched ruby lasers tended to be slow, expensive, and required a great deal of maintenance. Several case reports documenting aesthetic and congenital pediatric tattoo removal with a reengineered version of the 694-nm Q-switched ruby laser (Sinon) are presented.

Dr. Bernstein is Clinical Associate Professor of Dermatology, University of Pennsylvania, Philadelphia, and is in private practice, Bryn Mawr, Pennsylvania. Dr. Adrian is Director, Center for Laser Surgery, Washington, DC.

Dr. Bernstein is Director, Candela Corporation. Dr. Adrian reports no actual or potential conflict of interest in relation to this article.

CASE REPORTS

Patient 1

A 32-year-old white woman with Fitzpatrick skin type I presented for removal of a black tattoo on her back (Figure 1A). The patient was treated with the Sinon Q-switched ruby laser. Immediately prior to each laser session, the treatment site was cleaned with hydrogen peroxide and anesthetized with lidocaine 1% plus epinephrine. A clear hydrogel dressing was applied (with the plastic barrier removed from both sides) to protect the epidermis, reduce bleeding and skin fragmentation, and prevent aerosolization of skin fragments and blood. The patient underwent 7 laser treatments administered at 6-week intervals. The fluence was gradually increased over the course of treatment from a starting level of 2 J/cm² to a maximum of 6 J/cm² (average fluence, 5.1 J/cm²). A 5-mm spot size was used, and treatments were administered with a repetition rate of 2 pulses per second. Following laser treatment, the hydrogel dressing was taped in place, and the patient was instructed to apply a healing ointment along with a nonstick bandage held in place with paper tape. Treatment resulted in complete clearance of the tattoo (Figure 1B).

Patient 2

A 24-year-old white woman with Fitzpatrick skin type II presented for removal of a black tattoo (Figure 2A). The tattoo was several years old and easily visible when she wore sleeveless shirts. The patient underwent

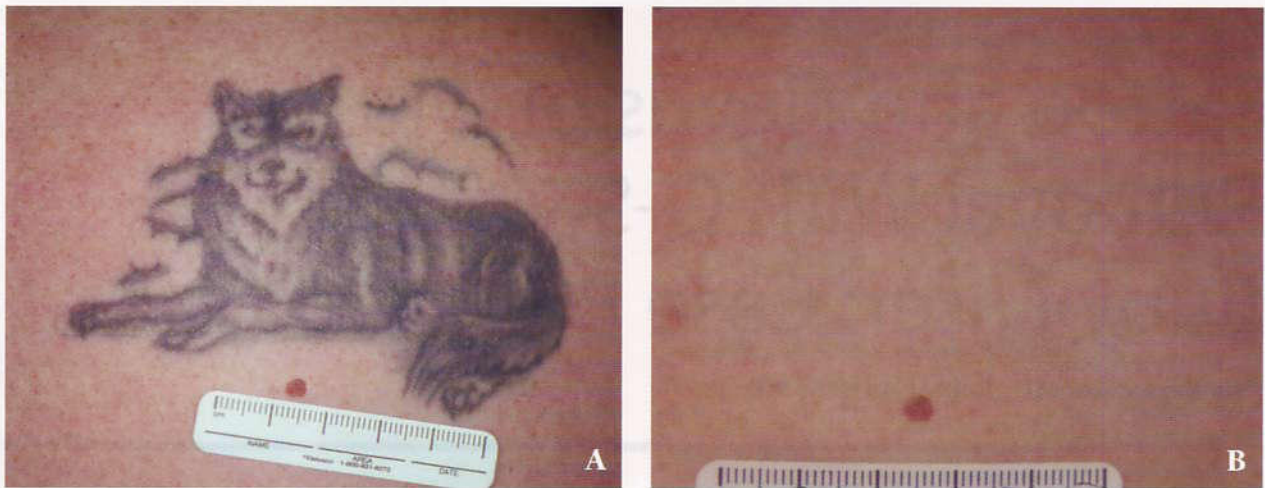


Figure 1. Black tattoo on the back of a 32-year-old woman with Fitzpatrick skin type I (patient 1) before (A) after 7 treatments with the Sinon Q-switched ruby laser administered at 6-week intervals (B).

8 treatments with the Sinon Q-switched ruby laser (Figure 2B). Prior to each session, the treatment area was anesthetized with lidocaine 1% plus epinephrine and covered with a hydrogel dressing as described in patient 1. A 5-mm spot size was used during each treatment, and fluence ranged from a starting level of 2.5 J/cm² to 6 J/cm² during subsequent treatments (average fluence, 5.1 J/cm²). Some hypopigmentation was

evident immediately following treatment but resolved within 3 months of the last treatment.

Patient 3

An 18-year-old man with Fitzpatrick skin type II presented with a blue-green tattoo on his back (Figure 3A). The patient underwent 3 treatments with the Sinon Q-switched ruby laser with intervals of 4 to 8 weeks

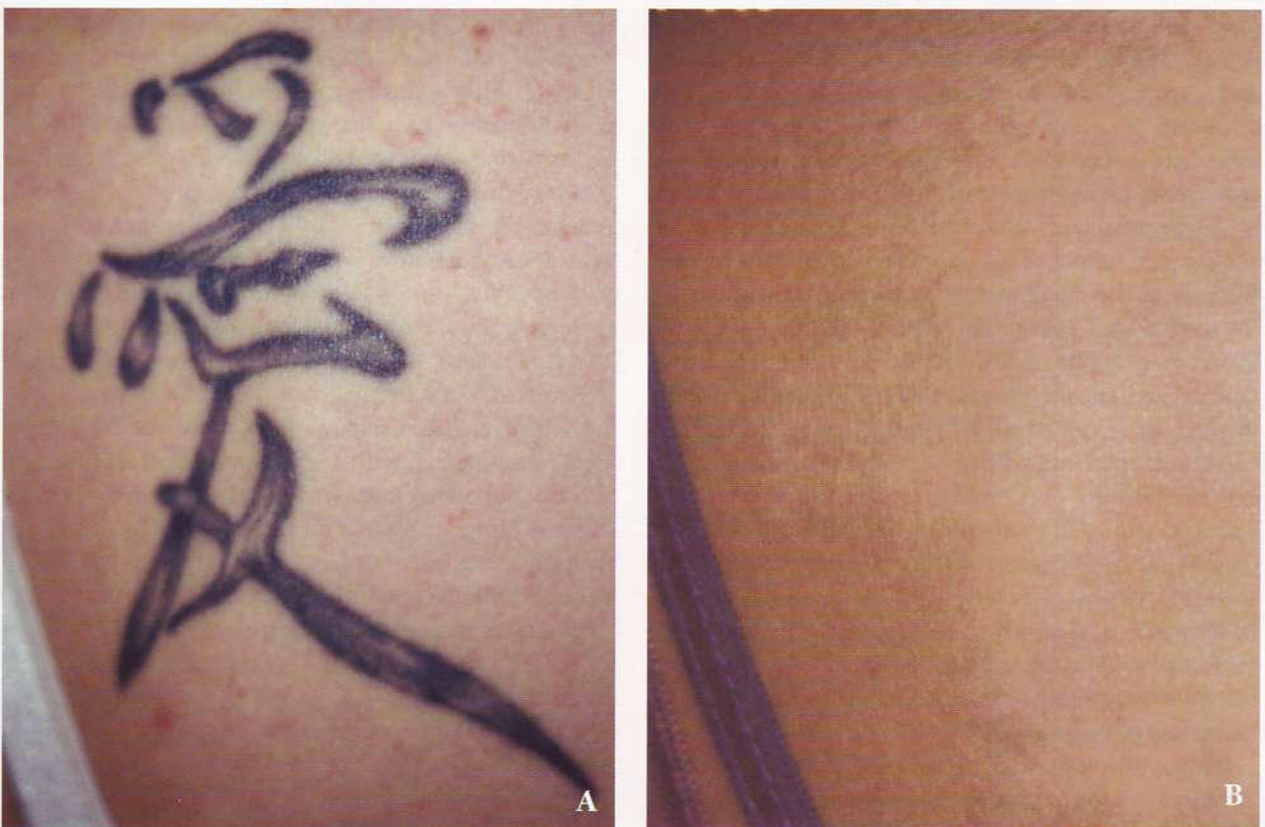

Figure 2. Patient 2 before (A) and after 8 treatments with the Sinon Q-switched ruby laser (B).

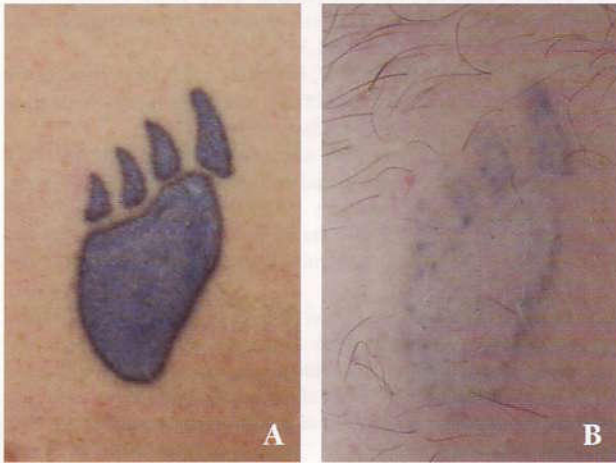

Figure 3. Blue-green tattoo located on the back of an 18-year-old man (patient 3) before (A) and after 3 treatments with the Sinon Q-switched ruby laser administered at 4- to 8-week intervals (B).

between each session (Figure 3B). A 5-mm spot size and an initial fluence of 3 J/cm², which was increased to 5 J/cm² over the course of treatment, were used. The patient experienced no treatment-related adverse events.

Patient 4

An 18-month-old girl with Fitzpatrick skin type II and extensive nevus of Ota (Figure 4A) underwent 3 treatments with the Sinon Q-switched ruby laser over the course of 9 months (Figure 4B). Topical lidocaine 2.5% and prilocaine 2.5% cream was applied prior to each treatment. Fluence ranged from 4.5 to 6.0 J/cm², and a 5-mm spot size was used. Sedation was not needed, as the child was held during each session. No complications were reported.

COMMENT

The motivations for tattoo removal are as varied as the reasons for tattoo application. However, often in the case of aesthetic tattoos, removal is desired because the patient no longer likes the image or it no longer suits his/her personality.⁶ Other patients may be seeking social assimilation.³ Regardless of the motivation, the demand is not for tattoo removal alone. Patients also expect the skin's texture, color, and overall appearance to remain unchanged. This presents a clinical challenge because treatment with many of the technologies currently available can result in scarring.¹ The Q-switched ruby laser had been a mainstay of laser tattoo removal in the past, but expense and reliability issues limited its use.

The development of the Sinon 694-nm Q-switched ruby laser has reintroduced this technology, reopening avenues for the removal of all types of tattoos, including

decorative, cosmetic (ie, permanent makeup), and traumatic. As described in patient 4, the Sinon laser can also be used to remove congenital lesions such as nevus of Ota. The Sinon laser offers a wide range of fluences, rapid pulse frequencies of up to 2 Hz, divergent beam technology, and a pulse width of 20 ns. Results obtained with this laser are consistent with and possibly superior to those achieved with the previous generation of Q-switched ruby lasers.^{1,3,7-11}

The Q-switched ruby laser was the first selective laser to be used for removing tattoos and pigmented lesions^{12,13} and is extremely effective in removing black and blue tattoo pigments. Taylor et al¹⁴ demonstrated clearing of amateur and professional tattoos using a Q-switched ruby laser (pulse duration, 40 to 80 ns; fluence, 2.5 to 8.0 J/cm²). The laser produced clearing in 78% of amateur tattoos and 23% of professional tattoos, with one scarring incident. Scheibner et al¹⁵ used the Q-switched ruby laser to remove 101 amateur and 62 professional tattoos and found the best response in amateur tattoos, with complete or near complete clearance in 87% (88/101) of the patients treated. The laser produced substantial removal or better in 40% (25/62) of the professional tattoos. No scarring was reported.¹⁵ Kilmer and Anderson¹⁶ reported adequate removal of blue, black, and green pigments with the Q-switched ruby laser.

The Sinon offers several advantages over previous Q-switched ruby lasers—a divergent beam and fluences ranging from 2 J/cm² to 30 J/cm², and, at 73 kg (approximately 160 lb), it is at least half the weight of its predecessors. The results achieved in our practices are comparable to those reported in the literature; however, the new design makes this device easier to use than previous models, and because it does not require water cooling, it may be more cost-effective. Moreover, it has

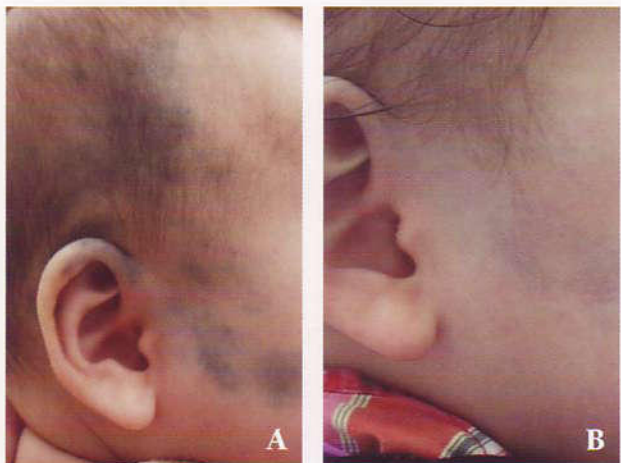

Figure 4. An 18-month-old girl with an extensive nevus of Ota (patient 4) before (A) and after 3 treatments with the Sinon Q-switched ruby laser administered over a 9-month period (B).

